



International Journal of
Experimental Pharmacology

www.ijepjournal.com

STUDY OF COURSE AND VARIANT BRANCHES OF BRACHIAL ARTERY

Sharadkumar Pralhad Sawant*

Professor and Head, Department of Anatomy, K.J.Somaiya Medical College, Somaiya Ayurvihar, Eastern Express Highway, Mumbai-400 022, Maharashtra, India.

ABSTRACT

Aim to study the variant course and variant branches of brachial artery. 100 upper limbs of 50 donated embalmed cadavers (45 males & 5 females) of age group ranging from 70 to 80 years were dissected in the department of Anatomy at K. J. Somaiya Medical College, Sion, Mumbai, INDIA. The variant course and variant branches of brachial artery was observed in 2 specimens. The neuro-muscular pattern in the arm was also observed. The photographs of the variant course and variant branches of brachial artery were taken for proper documentation. The variant course and variant branches of brachial artery were observed in 2 specimens. The brachial artery terminated in the cubital fossa into radial and common interosseous arteries. The radial artery had normal course and branches. The common interosseous artery was deeper and gave anterior and posterior ulnar recurrent arteries, and terminated into anterior and posterior interosseous arteries. The unusual large branch from the brachial artery was a variant of ulnar artery, arose from the lateral side of the brachial artery, descended on the lateral side up to the cubital fossa and crossed the fossa from lateral to medial, superficial to median nerve. It then descended superficial to the muscles arising from medial epicondyle of the humerus and was covered by the deep fascia of the forearm, pierced the deep fascia proximal to the wrist, crossed the flexor retinaculum, and formed the superficial palmar arch. Throughout its course, this artery gave no branch. There was no associated altered anatomy of the nerves observed in the specimen. The knowledge of presence of the unusual origin of the ulnar artery from the brachial artery in the axilla may be clinically important for clinicians, surgeons, orthopaedicians and radiologists performing angiographic studies.

Keywords: Brachial artery, Superficial antebrachial artery, Superficial brachial artery, Superficial ulnar artery, Ulnar artery.

INTRODUCTION

The brachial artery ends in the cubital fossa by dividing into radial and ulnar arteries. At the elbow, the ulnar artery sinks deeply into the cubital fossa and reaches the medial side of the forearm midway between elbow and wrist. The common interosseous artery is a short branch of the ulnar, passes back to the proximal border of the interosseous membrane and divides into anterior and posterior interosseous arteries. Anterior interosseous artery descends on the anterior aspect of the interosseous

membrane with the median nerve's anterior interosseous branch. Median artery, a slender branch from anterior interosseous artery, accompanies and supplies the median nerve.

MATERIALS AND METHODS

100 upper limbs of 50 donated embalmed cadavers (45 males & 5 females) of age group ranging from 70 to 80 years were dissected in the department of Anatomy at K. J. Somaiya Medical College, Sion, Mumbai, INDIA. The variant course and variant branches of brachial artery was observed in 2 specimens. The neuro-muscular pattern in the arm was also observed. The photographs of the variant

Corresponding Author

Sharadkumar Pralhad Sawant
EMail Id: drspsawant@gmail.com

course and variant branches of brachial artery were taken for proper documentation.

Observations

The variant course and variant branches of brachial artery were observed in 2 specimens. The brachial artery terminated in the cubital fossa into radial and common interosseous arteries. The radial artery had normal course and branches. The common interosseous artery was deeper and gave anterior and posterior ulnar recurrent arteries, and terminated into anterior and posterior interosseous arteries.

The unusual large branch from the brachial artery was a variant of ulnar artery, arose from the lateral side of the brachial artery, descended on the lateral side up to the cubital fossa and crossed the fossa from lateral to medial, superficial to median nerve. It then descended superficial to the muscles arising from medial epicondyle of the humerus and was covered by the deep fascia of the forearm, pierced the deep fascia proximal to the wrist, crossed the flexor retinaculum, and formed the superficial palmar arch. Throughout its course, this artery gave no branch. There were no associated altered anatomy of the nerves observed in the specimen.

Figure 1. Showing the photographic presentation of the unusual course of the brachial artery.

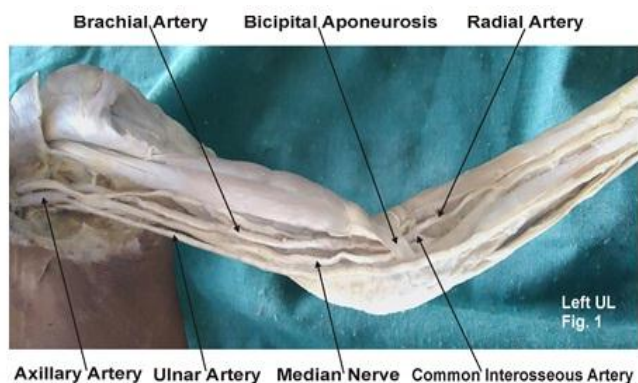
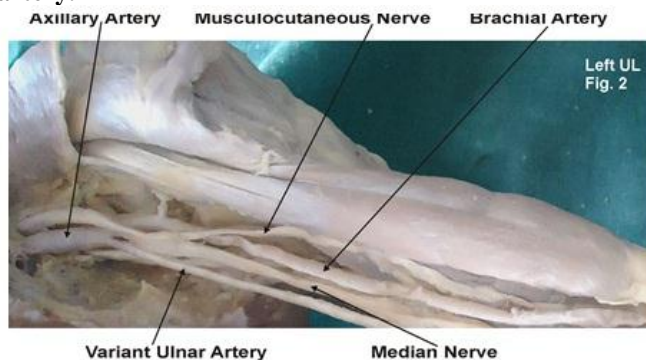


Figure 2. Showing the photographic presentation of the unusual origin of the ulnar artery from the brachial artery.



DISCUSSION

The variations in branching pattern of axillary artery are a rule rather than exception [2-16]. Variant branches may arise from the brachial artery [17]. Ulnar artery was found to deviate from its usual mode of origin in one in thirteen cases; frequently it sprang from the lower part of the brachial artery; the position of the ulnar artery in the forearm was more frequently altered; in cases of high origin, it invariably descended over the muscles arising from the medial epicondyle of the humerus and was covered by the deep fascia of the forearm [2]. The present case of ulnar artery is somewhat similar to the variations presented in Quain's Anatomy [2]. If the brachial artery is taken to terminate into radial and ulnar arteries, the embryological basis of the existing ulnar artery and the origin and course of the unusual branch of the brachial artery, replacing the ulnar artery in the present study, is as follows.

Embryological Basis:

Primitive axis artery and superficial brachial artery are implicated in the morphogenesis of the arteries of the upper limb [3, 18]. The seventh cervical intersegmental artery forms the axis artery of the upper limb and persists in the adult to form the axillary, brachial, and interosseous arteries. Transiently, the median artery arises as a branch of the interosseous artery, begins to regress and remains as a

residual artery accompanying the median nerve [18]. Radial and ulnar arteries are later additions to the axis artery. An ulnar artery and a median artery are branches of the axis artery [8]. A superficial brachial artery is a consistent embryonic vessel, coexisting or not with the brachial artery [19]. It has two terminal branches, a lateral that continues as a part of the definitive radial artery (20) and a medial, superficial antebrachial artery, which divides into median and ulnar artery branches, which are the trunks of origin of the median and ulnar arteries. These trunks of deep origin predominate and the superficial arteries regress (8). In the present study, the axis artery had formed the interosseous artery and given the trunks of the median and ulnar arteries. The ulnar branch of the superficial antebrachial artery persists independently, without its usual anastomosis to the branch of the axis artery, as the large lateral branch of the brachial artery and the superficial ulnar artery, which is found in the distal part of the forearm and joins the superficial palmar arch. If the brachial artery is taken to terminate into radial and interosseous arteries, the simpler embryological basis of the interosseous artery and the origin and course of the unusual branch of the brachial artery, replacing the ulnar artery, is the following. It appears probable that the abnormal arrangement results from early obstruction of the ulnar artery below the origin of the interosseous, and the development of a superficial

vas aberrans, which replaces the portion of vessel below the obstruction and unites with the brachial.

Clinical Significance

The interosseous artery in such cases of abnormality thus comprises not only the interosseous artery but also the portion of ulnar artery above the obstruction. And, in accordance with this view, the recurrent branches are derived from it [2]. The present anomaly is very rare and does not seem to have been reported. This case is of significance. Such an artery may present a superficial pulse and a hazard to venipuncture [21] and lead to intra-arterial injections or ligature instead of the vein in the cubital fossa [22, 23] Variation in the branching pattern of the brachial artery is of significance in cardiac catheterization for angioplasty, pedicle flaps, arterial grafting or brachial pulse.

CONCLUSION

The knowledge of presence of the unusual origin of the ulnar artery from the brachial artery in the axilla may be clinically important for clinicians, surgeons, orthopaedicians and radiologists performing angiographic studies. Undoubtedly, such variations are important for diagnostic evaluation and surgical management of vascular

diseases and injuries. These variations are compared with the earlier data & it is concluded that variations in branching pattern of axillary artery are a rule rather than exception. Therefore both the normal and abnormal anatomy of the region should be well known for accurate diagnostic interpretation and therapeutic intervention.

ACKNOWLEDGEMENT

The authors wish to convey his sincere thanks to our Dean Dr. Geeta Niyogi Madam for her valuable help, support and inspiration. I am also thankful to Mr. M. Murugan. Author also acknowledges the immense help received from the scholars whose articles are cited and included in references of this manuscript. The author is also grateful to authors / editors / publishers of all those articles, journals and books from where the literature for this article has been reviewed and discussed.

Competing Interests

The author declares that he has no competing interest.

Authors' contributions:

SPS draft the manuscript, performed the literature review & obtained the photograph for the study.

REFERENCES

1. Williams PL, Bannister LH, Berry MM, Collins P, Dyson M, Dussek JE, Ferguson MWJ. Gray's Anatomy, In, Cardiovascular system. Gabella, G. Edr. 40th Edn, 2008, Churchill Livingstone, London, Edinburgh, 1537-1540.
2. Thane GD. Quain's elements of Anatomy. In, Arthrology- Myology-Angiology. 10th Edn; 1892, Longman, Green, and Co. London, 445.
3. Schwyzer AG and DeGaris CF. Three diverse patterns of the arteria brachialis superficialis in man, 1935. *Anatomical Record*, 63, 405- 416.
4. Mc Cormack LJ, Caldwell MD and Anson BJ. Brachial antebraichial arterial patterns. *Surgery Gynecology and Obstetrics*, 96, 1953, 43-54.
5. Coleman SS and Anson BJ. Arterial patterns in the hand based upon a study of 650 specimens. *Surgery Gynecology and Obstetrics*, 1926, 113, 409-424.
6. Lippert, H. and Pabst, R, Arterial variations in Man. Bergmann, *Munich*, 1985, 66-73.
7. Poteat, W.L, Report of a rare human variation, Absence of the radial artery. *Anatomical Record*, 214, 1986, 89-95.
8. Rodriguez-Baeza A, Nebot J, Ferreira B, Reina F, Perez J, Sanudo JR and Rolg, M, An anatomical study and ontogenic explanation of 23 cases with variations in the main pattern of the human brachio-antebraichial arteries. *Journal of Anatomy*, 187, 1995, 473-479.
9. Aharinejad S, Nourani F and Hollensteiner H, Rare case of high origin of ulnar artery from the brachial artery. *Clinical Anatomy*, 10, 1997, 253-258.
10. Patnaik VVG, Kalsey G and Singla RK. Anomalous course of radial artery and a variant of deep palmar arch, A case report. *Journal of the Anatomical Society of India*, 49(1), 2000, 54-57.
11. Patnaik VVG, Kalsey G and Singla RK. Superficial palmar arch duplication, A case report. *Journal of the Anatomical Society of India*, 49(1), 2000, 63-66.
12. Patnaik VVG, Kalsey G and Singla RK. Trifurcation of brachial artery-A case report. *Journal of the Anatomical Society of India*, 50(2), 2001, 163-165.
13. Patnaik VVG, Kalsey G and Singla RK. Bifurcation of axillary artery in its 3rd part-A case report. *Journal of the Anatomical Society of India*, 50(2), 2001, 166-169.
14. Celik HH, Germus, G, Aldur MM and Ozcelik M, Origin of the radial and ulnar arteries, variation in 81 arteriograms. *Morphologie*, 85, 2001, 25-27.
15. Clerve A, Kahn M, Pangilinan AJ and Dardik H. Absence of the brachial artery, report of a rare human variation and review of upper extremity arterial anomalies. *Journal of Vascular Surgery*, 33, 2001, 191-194.

16. Suganthy J, Koshy S, Indrasingh I. and Vettivel S, A very rare absence of radial artery, A case report. *Journal of the Anatomical society of India*, 51(1), 2002, 61-64.
17. Huber GC. Piersol's Human Anatomy. In, The vascular system 9th Edn. 1930, Vol 1, J. B. Lippincott Co. Philadelphia, 767-791.
18. Singer E. Embryological pattern persisting in the arteries of the arm. *Anatomical Record*, 55, 1933, 403-409.
19. Tountas CHP and Bergman RA. Anatomic Variations of the upper extremity. Churchill Livingstone, 1993, New York, 196-210.
20. Vancov V. Une variete extremement complexe des arteres du member superieur chez un foetus humain. *Anatomischer anzeiger*, 109, 1961, 400-405.
21. Hazlett JW. Superficial ulnar artery with reference to accidental intra-arterial injection. *Canadian Medical Association Journal*, 61, 1949, 289-293.
22. Pabst R and Lippert H, Belderseitiges Vorkommen von A. brachialis superficialis, ulnaris superficialis and A. mediana. *Anatomischer Anzeiger*, 123, 1968, 223-226.
23. Thoma A and Young JEM. The superficial ulnar artery "trap" and the free forearm flap. *Annals of Plastic Surgery*, 28, 1992, 370-372.